

# Mammometrics: The Standardization of Aesthetic and Reconstructive Breast Surgery

Oren M. Tepper, M.D.  
Jacob G. Unger, M.D.  
Kevin H. Small, M.D.  
Daniel Feldman, B.A.  
Naveen Kumar, M.D.  
Mihye Choi, M.D.  
Nolan S. Karp, M.D.  
*New York, N.Y.*

**T**he goal of cosmetic and reconstructive breast surgery is to create symmetric and aesthetically pleasing results in a reproducible manner. Although continued progress is dependent on the ability of plastic surgeons to accurately assess surgical outcomes, available methods to objectively evaluate aesthetic and reconstructive breast surgery are limited. This is quite different from other areas of plastic surgery, such as craniomaxillofacial surgery, that often use precise skeletal measurements to provide a platform for preoperative and postoperative analysis. In comparison, systematic evaluation of breast surgery has yet to be standardized.

With the advent of three-dimensional photography, objective soft-tissue analysis of the breast is now possible. Recent work from our group and others has validated the use of three-dimensional breast photography in various clinical arenas, including autologous breast reconstruction, prosthetic breast reconstruction, reduction mammoplasty, and augmentation mammoplasty.<sup>1-7</sup> Enthusiasm toward three-dimensional imaging technology has stemmed from the ability to not only obtain well-established breast measurements in an accurate manner, but also to generate measurements that were not previously possible with conventional tools, such as total breast volume, volumetric distribution, and breast projection. This article provides an overview of three-dimensional breast photography, with particular emphasis on its potential role to establish a standardized system for breast analysis. We introduce a new concept termed “mammometrics,” in which three-dimensional-based

breast measurements can be used to help guide operative planning, objectively analyze surgical results, and document postoperative changes that occur over time.

## LESSONS FROM CRANIOMAXILLOFACIAL SURGERY

The clinical utility of a standardized method for preoperative and postoperative measurements is perhaps best exemplified by the application of cephalometrics in craniofacial and orthognathic surgery. Normative data of the bony facial skeleton help in the planning, execution, and analysis of various procedures. During cephalometric analysis, anatomical landmarks of the facial skeleton are used to generate fixed planes and points (Fig. 1). Measurements are then generated to aid in determining the direction and extent to which structures or points need to be moved.<sup>8,9</sup> Today, cephalometrics is used for virtually all procedures that involve manipulation of the craniofacial skeleton.

Although the bony skeleton serves as the basis for craniomaxillofacial surgery, most procedures also involve an important component of soft-tissue rearrangement. Given this relationship, newer techniques for three-dimensional cephalometrics are being developed, which correlate standard skeletal measurements along with overlying soft-tissue anatomy.<sup>10-13</sup> Interestingly, Guyuron previously introduced a similar theme in “soft-tissue cephalometrics,” whereby he described a method for creating a numeric guide for rhinoplasty surgery based on cephalometric principles and soft-

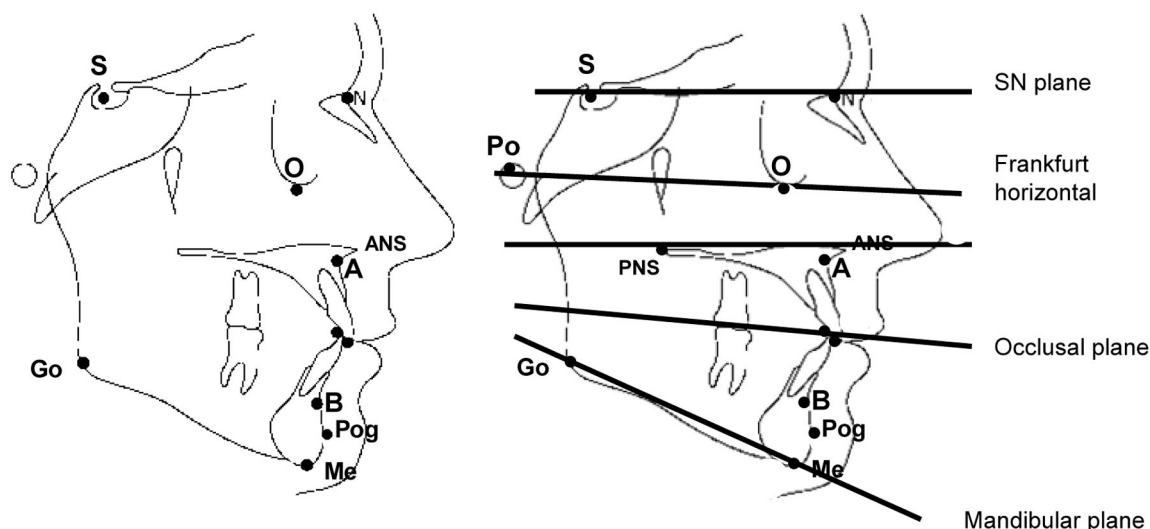
*From the Institute of Reconstructive Plastic Surgery, New York University Medical Center.*

*Received for publication December 10, 2008; accepted July 27, 2009.*

*Copyright ©2009 by the American Society of Plastic Surgeons*

DOI: 10.1097/PRS.0b013e3181c4966e

**Disclosures:** *None of the authors has a financial interest to declare in relation to the content of this article.*



**Fig. 1.** Representative images of a cephalometric tracing. Commonly identified points (*left*) and planes (*right*) used in the planning of and analysis of craniomaxillofacial surgery are shown. S, sella; O, orbitale; N, nasion; ANS, anterior nasal spine; PNS, posterior nasal spine; A, a point; B, b point; G, gonion; Po, pogonion; Me, mentale.

tissue measurements.<sup>14</sup> In this report, he defined a new series of proportions, lines, and values to objectively describe the changes that should be made to the nose to achieve an aesthetically pleasing result. This work highlights the potential, in our specialty, to achieve the degree of objective analysis that is exhibited by craniomaxillofacial surgery.

## HISTORY OF BREAST MEASUREMENTS

Previous attempts to standardize breast dimensions have focused on linear measurements, including base diameter, inframammary fold-to-nipple distance, and sternal notch-to-nipple distance. Although these parameters are applied clinically today in breast reconstruction and cosmetic procedures, other variables that define breast volume and shape are largely underused.

Early descriptions of breast volume measurements include the use of mathematical equations or anthropomorphic measurements.<sup>15</sup> Historically, the Grossman-Roudner device provided a method for breast volume measurement, but this has been criticized for its inability to account for tissue lateral to the pectoral fold or to obtain a volume measurement in excessively small or large breasts.<sup>16,17</sup>

More recently, Archimedes' principle of buoyancy was introduced as a way to determine breast volume through the concepts of both mathematics and displacement.<sup>18,19</sup> Tezel and Numanoglu<sup>19</sup> in 2000 described a homemade water displacement device that successfully measured breast vol-

ume, but this does not appear to be practical for the average practitioner. Plaster and thermoplastic casts have also been described as a means of assessing breast volume and symmetry.<sup>20,21</sup> However, similar to water displacement techniques, casting techniques are relatively cumbersome, subject to user discrepancy by the method in which the device is placed, and limited in the data provided.

## THREE-DIMENSIONAL IMAGING AND BREAST MEASUREMENTS

A number of recent studies suggest that three-dimensional photography provides a unique approach for breast analysis.<sup>2,3,6,22,23</sup> Losken et al. demonstrated the utility of three-dimensional photography for assessing breast volume, as mastectomy weights closely correlated with preoperative three-dimensional volume measurements.<sup>4</sup> Kovacs et al. reported similar findings by comparing volumes based on three-dimensional imaging and magnetic resonance imaging.<sup>5,22,24</sup>

Three-dimensional imaging affords the ability to calculate not only breast volume but also other clinically relevant breast parameters. Isogai et al. reported that three-dimensional images could be used to objectively assess bilateral breast symmetry.<sup>6,25</sup> Ongoing work in our laboratory has identified other ways of objectively assessing breast size and shape with three-dimensional imaging. Based on standard breast measurements, we believe this technology can be used as a method to objectively determine soft-tissue changes of the breast follow-

ing surgery.<sup>17</sup> For example, we recently reported our experience with 30 patients undergoing reduction mammoplasty and showed for the first time objective preoperative and postoperative three-dimensional breast data.<sup>3</sup> Three-dimensional analysis of the breast therefore represents a significant advance relative to the aforementioned techniques, which primarily focus on breast volume and fail to address shape, contour, and relative position on the chest wall.

As techniques for three-dimensional breast analysis continue to unfold, it has become apparent to our group that the role of three-dimensional imaging in breast surgery closely resembles that of cephalometrics in craniofacial surgery. In this article, we highlight our approach to performing systematic three-dimensional measurements in aesthetic and reconstructive breast surgery patients. These data points provide a potential foundation for a standardized system of breast analysis, and thus we introduce and propose a new concept of mammometrics.

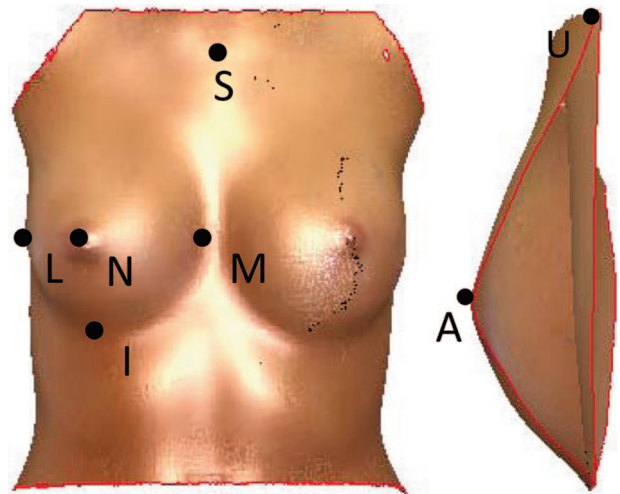
## MAMMOMETRICS

Mammometrics may be defined as the establishment of fixed planes and points to perform objective breast measurements. By creating a set of standard soft-tissue landmarks of the breast and bony anatomical landmarks of the torso, changes to the shape, contour, volumetric distribution, and position of the breast on the chest can be assessed quantitatively for the first time. Numerical values can now be assigned to the various changes in breast dimension. In the following discussion, we introduce our approach to mammometrics that involves (1) the identification of fixed points and planes and (2) the generation of volumetric, surface, and vector measurements that define breast contour, size, and position on the chest wall.

### Mammometric Points

Various anatomical points are first identified on a three-dimensional breast image (Fig. 2). On the anteroposterior view, the following points are marked:

- N point (nipple point): The center of each nipple.
- S point (sternal point): The sternal notch.
- I point (inferior point): The inferiormost point of each breast.
- L point (lateral point): The lateral inframammary fold point.
- M point (medial point): The medial inframammary fold point.



**Fig. 2.** Mammometric points. (Left) These images show common surface landmarks used in mammometrics. The nipple (N), sternal (S), inferior (I), lateral (L), and medial (M) points are shown on an anterior view. (Right) The A point (anterior) and the U point (upper) are shown on a sagittal cross-section of the breast.

Using the sagittal view, the following points are identified:

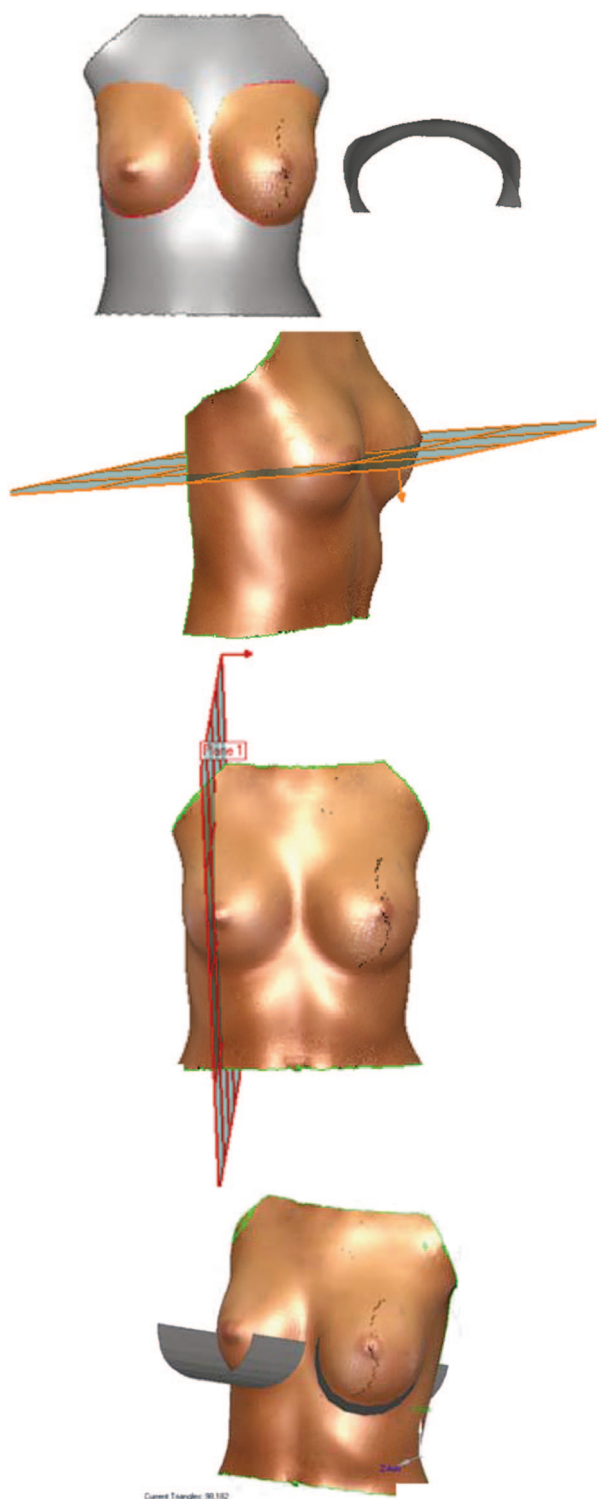
- A point (anterior point): The anteriormost point of each breast. This point may or may not correlate with the N point.
- U point (upper point): The superior, or upper point at which the breast takes off from the chest wall.

### Mammometric Planes

The three-dimensional image of the patient is then oriented on *x-y-z* coordinate axes, and the following planes are created (Fig. 3):

- Chest wall plane (CW plane): A curved plane that matches the curvature of the patient's torso, with the breasts removed.
- Horizontal-split plane (HS plane): An *xz* coordinate plane through both right and left points of the inframammary fold.
- Vertical-split plane (VS plane): A *yz* coordinate, or sagittal, plane through the center of each breast determined by the midpoint of the base width.
- Inframammary fold plane (IMF plane): The natural inframammary fold of each patient.

Of note, mammometric planes are unique in that they are established on a patient's preoperative (native) three-dimensional images only. Unlike mammometric points, which are marked on each image, fixed mammometric planes are transferred



**Fig. 3.** Mammometric planes. (Above) Shown here are multiple angles of the curved chest wall plane with and without a breast overlay. This curvature is based on the individual's torso. (Second row) The horizontal-split plane is an xy plane that intersects the lateral borders of the inframammary fold. (Third row) The vertical split plane is a yz plane, or sagittal plane, through the midpoint of the breast width. (Below) The inframammary plane is a plane through the patient's natural inframammary fold.

to postoperative images such that consistent measurements and relative comparisons can be made.

### Mammometric Volumes

From the above data points and planes, a series of measurements can be made on the breast. We suggest the following volume measurements as the basic tenets for a mammometric data set (Fig. 4):

**Total breast volume:** The complete volume of each breast. This is determined by overlaying the breast onto the chest wall and creating a closed three-dimensional object.

**Vertical-split volumes:** The volume of each breast divided into a medial pole and a lateral pole, as defined by the vertical-split volume plane of each breast.

**Horizontal-split volume:** The volume of each breast divided into an upper and lower pole. The upper and lower poles are defined by the HS plane; above the HS plane is the upper pole, and below the plane is the lower pole.

### Mammometric Vectors and Surface Distances

The following distances represent important clinical measurements to obtain from three-dimensional images (Fig. 5):

**CW-A (chest wall to anterior) distance:** The most direct vector from the chest wall plane to the A point that gives the maximal projection of the breast.

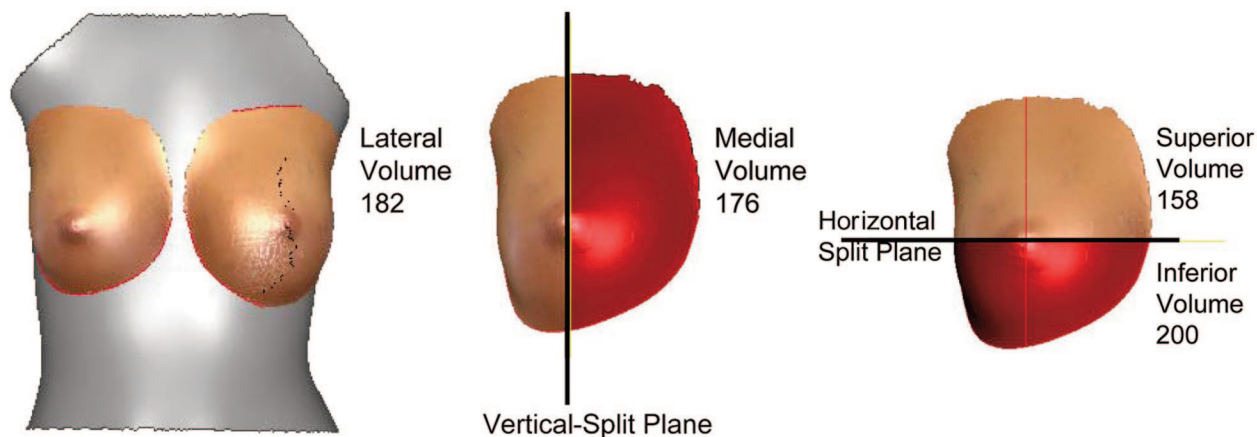
**HS-to-I (horizontal-split to inferior) distance:** The distance from the horizontal split plane to the I point, or the inferiormost point of the breast. This may be calculated as a surface measurement or as a direct vector measurement.

**S-to-N distance:** The distance from the S point to the N point. Similarly, this may be generated as either a surface distance, similar to what is commonly performed today, and a vector measurement.

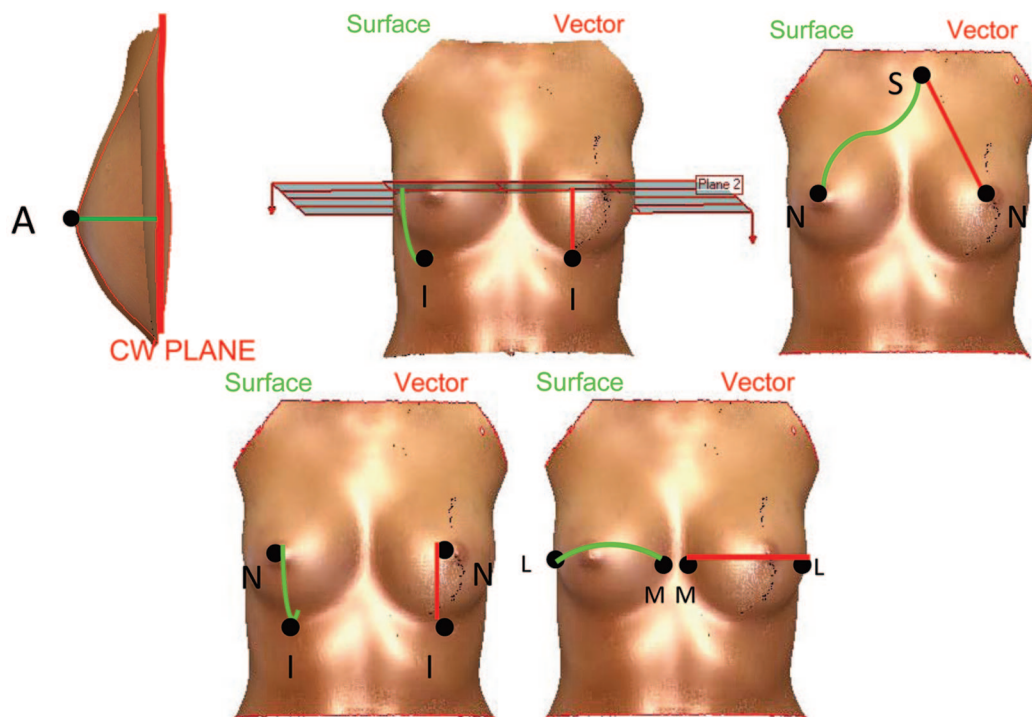
**N-to-I distance:** The distance from the N point to the I point. The N-to-I surface distance wraps around the inferior pole of the breast and describes the length of tissue between the N point and the inferiormost point of the breast. The most direct path from these points represents the N-to-I vector distance.

**L-to-M distance:** The most direct vector from the L point to the M point on each breast represents the width of the breast between the medial and lateral borders of the inframammary fold. A surface distance of the width of the





**Fig. 4.** Volume and split-volume mammometrics. Once total volumes are determined (*left*), the vertical- and horizontal-split planes can be used to create split volumes by dividing the breasts into medial and lateral poles (*center*), or superior and inferior poles (*right*), respectively.



**Fig. 5.** Mammometric vector and surface measurements. By using the points and planes described by mammometrics, clinically relevant surface and vector distances can be measured. Shown here are examples of the chest wall plane-to-anteriormost point (CW-A) distance, the horizontal-split plane-to-inferiormost point (HS-I) distance, the sternal notch-to-nipple point (S-N) distance, the nipple-to-inferiormost point (N-I) distance, and the lateral IMF point-to-medial IMF point (L-M) distance. IMF, inframammary fold.

breast from the L point to the M point can also be calculated.

### CLINICAL APPLICATIONS OF MAMMOMETRICS

A comprehensive overview of mammometric measurements is shown in Figure 6. Below, we

highlight scenarios in which these measurements can be applied clinically to aesthetic and reconstructive breast surgery.

#### Breast Reduction

The application of mammometrics enables surgically induced changes in the breast to be

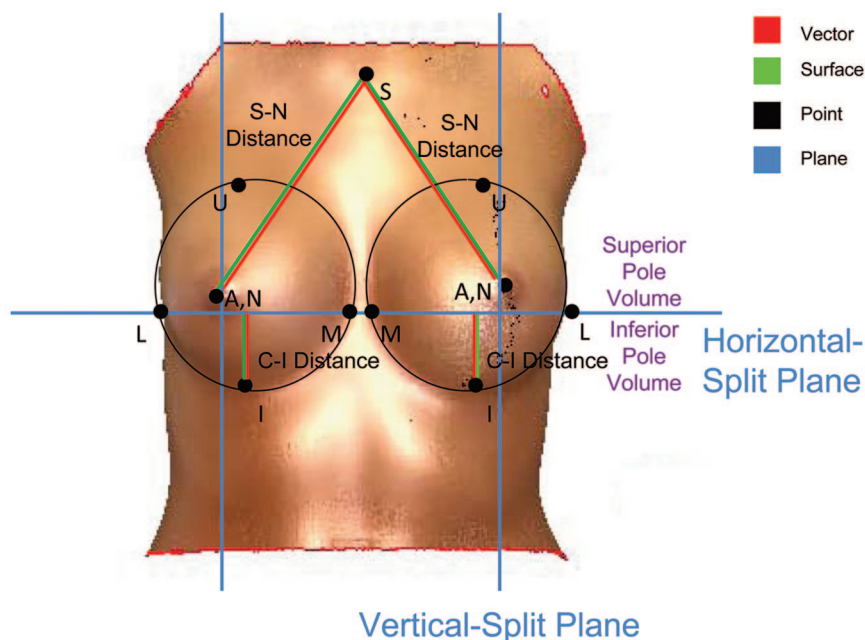
described mathematically. With reduction mammoplasty, preoperative volumes can be compared with postoperative results, and changes in the shape of the breast can be quantified. Volumetric distribution (i.e., upper and lower pole volume) gives insight into the shape of the breast by split-horizontal plane. For the first time, breast volume redistribution after surgery can be discussed in percentages and numbers. Further along the postoperative timeline, as the breast undergoes pseudoptosis, the long-term changes in volumetric distribution can also be described quantitatively. We recently demonstrated in 12 reduction mammoplasty patients the occurrence of pseudoptosis in the first year after surgery, but not in the subsequent year.<sup>7</sup>

Three-dimensional mammometrics may also be applied to surgical planning in breast reduction procedures. For example, surgeons may choose to base resection weights on volumetric measurements rather than subjective estimates, which can be particularly helpful for patients with significant asymmetry. Of note, three-dimensional mammometric analysis of the breast can be performed regardless of degree of ptosis. For example, in our most recent study of reduction mammoplasty patients, all patients categorized as either grade II (58 percent) or grade III (42 percent)

ptosis had images successfully captured with the quality necessary for full volumetric and mammometric analysis.<sup>7</sup> As three-dimensional data analysis of pseudoptosis or bottoming out continues to be evaluated, this phenomenon can be described objectively in terms of discrete changes in specific parameters (i.e., S-N distance, C-I distance, N-I distance, and change in split volume percentages). This creates the possibility for mammometrics to correlate expected future change in breast shape in the years following reduction mammoplasty. Ultimately, this may improve a surgeon's ability to determine how to reshape the breast to create an optimal long-term result. By correlating the subjective sense of aesthetics with mathematical data, the creation of a symmetric and pleasing result may be more easily achieved.

### Breast Reconstruction

In breast reconstruction, three-dimensional imaging and analysis is clinically valuable. Preoperative volumes of both the unaffected side and the premastectomy breast are helpful as a guide for sizing of the new breast. Also important is the symmetry of the reconstructed breast when compared with the unaffected breast in shape, nipple



**Fig. 6.** This is an overview of a single three-dimensional image summarizing standard mammometric points, planes, distances, and volumes. S, sternal notch; n, nipple point; A, anteriormost point; M, medial inframammary fold point; L, lateral inframammary fold point; C, chest wall; I, inferiormost point; U, uppermost point.

position, and position on the chest wall. By using mammometrics, a standardized set of data can be generated to help the surgeon achieve bilateral symmetry. These data can be helpful as a guide for selection of an implant by comparing the various parameters of the implant to the measurements one is trying to achieve. The chest wall-to-A point distance can guide in choosing the projection of an implant and the total volume and split volumes in addition to base diameters can help in choosing a specific implant style. Furthermore, three-dimensional measurements can be useful in planning for a contralateral symmetry procedure, by providing the surgeon with numeric values with which to base augmentation or reduction on the nondiseased breast. In addition, although not currently feasible, three-dimensional mammometrics may allow for better design of autogenous flaps by recognizing the volume, shape, and contour of the defect.

### Breast Augmentation

The application of mammometrics in augmentation mammoplasty is also encouraging. We have recently documented the extent to which breast augmentation changes breast shape. In a study of 28 augmented breasts, we show that breast volume increased in direct correlation to implant size.<sup>1</sup> However, comparison of shape and implant dimensions demonstrated that the true projection reached 20.9 percent less than the manufacturer-reported projection of the implant when placed *in vivo*.<sup>1</sup>

Another potential area where three-dimensional imaging may prove to be valuable is mastopexy-augmentation. Some surgeons support two-stage mastopexy-augmentation, whereas others believe a single-stage procedure can be performed with comparable outcomes. Unfortunately, it is difficult to draw conclusions from such studies given the lack of objective measurements that document preoperative breast morphology and the extent of operative changes. It is our belief that mammometric data provide concrete measurements from which comparisons can be made, and surgical guidelines may ultimately be devised.

Furthermore, with the ability to document *in vivo* implant dimensions through mammometric analysis, simulation of results through software designed to incorporate these new data may be a feasible idea. This allows the ability to create three-dimensional models of predicted results; software that generates three-dimensional images based on particular implant sizes and shapes are currently

being developed and released. Finally, similar to breast reconstruction and reduction surgery, mammometrics can be applied postoperatively to determine potential long-term changes in implant shape and position.

## DISCUSSION

The concept of mammometrics uses fixed planes and points from which clinically relevant data can be generated. The foundation of mammometrics mimics that of cephalometrics, which serves as a means of standardizing patient assessment in the preoperative or postoperative period. Although the application of three-dimensional imaging to breast surgery is a relatively new concept, a number of studies to date have validated the accuracy and reproducibility of this technology.<sup>2-6</sup> An important difference between mammometrics and cephalometrics is that the latter is based on normative data. Although various cephalometric databases are available for clinicians to use, such as the Bolton standard, mammometrics is currently limited to various parameters of the individual's breasts relative to preoperative or original data. It is our hope that this technique offers a standard approach with which to begin collection of these important data, and that eventually normative data sets based on numerous patients could be established.

One potential concern for the use of mammometrics is the skill set required to perform these measurements. Having performed a number of research studies to date, we believe that three-dimensional imaging in its current form is a relatively straightforward process and that the techniques required to perform these measurements are well within the computer skill set of most surgeons or office staff. Moreover, commercial software and hardware products are continuously being updated to achieve more user-friendly systems. A second concern may be the cost of three-dimensional cameras, which may fall in the range of \$20,000 to 60,000.<sup>2</sup> Currently available systems include Canfield (Canfield Imaging Systems, Fairfield, N.J.; [www.canfieldsci.com](http://www.canfieldsci.com)), 3dMD (Atlanta, Ga.; [www.3dmd.com](http://www.3dmd.com)), and Axis 3 (Boston, Mass.; [www.axis3.com](http://www.axis3.com)), and all give the user the ability to capture three-dimensional images and analyze them to various degrees. Other approaches to three-dimensional breast imaging such as purchasing separate imaging devices [i.e., Konica Minolta (Tokyo, Japan) Vivid 910<sup>2</sup>] and software (i.e., Geomagic Studio 10) (Geomagic, Research Triangle Park, N.C.; [www.geomagic.com](http://www.geomagic.com))



may allow the user to approach the lower end of the price spectrum.

One possible future application of mammometrics is its role as an aid in patient-surgeon communication and the management of expectations with a defined set of reference values. For instance, patients are currently informed of possible postoperative changes to the breast over time, such as bottoming out, without many true objective data. With the establishment of mammometric data sets, patients may be given more concrete guidelines regarding the average amount of pseudoptosis that occurs, and the expected time frame. If large series of mammometric data sets are established, surgeons will likely not need to rely on anecdotal or personal experience to discuss possible operative outcomes.

Despite the advantages and relative ease of three-dimensional imaging, it is worth noting that no amount of presurgical planning or data analysis will entirely replace the skill and vision of the operator. Other patient variables such as skin elasticity are not incorporated into the three-dimensional mammometric data. The surgeon must have the requisite skill and training to create an aesthetically pleasing result in any breast procedure. Nevertheless, we believe that this new system of analysis is a valuable adjunct to help optimize outcomes. With the application of mammometrics, we have the opportunity to transition toward a more objective approach to aesthetic and reconstructive breast surgery.

**Nolan S. Karp, M.D.**

New York University Medical Center  
305 East 47th Street, Suite 1A  
New York, N.Y. 10017  
nolan.karp@med.nyu.edu

#### ACKNOWLEDGMENT

*The authors thank Gina Bradshaw for her continued assistance with the research efforts.*

#### REFERENCES

1. Tepper OM, Small KH, Unger JG, et al. 3D analysis of breast augmentation defines operative changes and their relationship to implant dimensions. *Ann Plast Surg.* 2009; 62:570–575.
2. Tepper OM, Small K, Rudolph L, Choi M, Karp N. Virtual 3-dimensional modeling as a valuable adjunct to aesthetic and reconstructive breast surgery. *Am J Surg.* 2006;192: 548–551.
3. Tepper OM, Choi M, Small K, et al. An innovative three-dimensional approach to defining the anatomical changes occurring after short scar-medial pedicle reduction mammoplasty. *Plast Reconstr Surg.* 2008;121:1875–1885.
4. Losken A, Seify H, Denson DD, Paredes AA Jr, Carlson GW. Validating three-dimensional imaging of the breast. *Ann Plast Surg.* 2005;54:471–476; discussion 477–478.
5. Kovacs L, Yassouridis A, Zimmermann A, et al. Optimization of 3-dimensional imaging of the breast region with 3-dimensional laser scanners. *Ann Plast Surg.* 2006;56:229–236.
6. Isogai N, Sai K, Kamiishi H, Watatani M, Inui H, Shiozaki H. Quantitative analysis of the reconstructed breast using a 3-dimensional laser light scanner. *Ann Plast Surg.* 2006; 56:237–242.
7. Choi M, Unger J, Small K, et al. Defining the kinetics of breast pseudoptosis after reduction mammoplasty. *Ann Plast Surg.* 2009;62:518–522.
8. Hurst CA, Eppley BL, Havlik RJ, Sadove AM. Surgical cephalometrics: Applications and developments. *Plast Reconstr Surg.* 2007;120:92e–104e.
9. McIntyre GT, Mossey PA. Size and shape measurement in contemporary cephalometrics. *Eur J Orthod.* 2003;25:231–242.
10. Park SH, Yu HS, Kim KD, Lee KJ, Baik HS. A proposal for a new analysis of craniofacial morphology by 3-dimensional computed tomography. *Am J Orthod Dentofacial Orthop.* 2006; 129:600.e23–600.e34.
11. Baik HS, Lee HJ, Lee KJ. A proposal for soft tissue landmarks for craniofacial analysis using 3-dimensional laser scanning. *World J Orthod.* 2006;7:7–14.
12. Hajeer MY, Ayoub AF, Millett DT, Bock M, Siebert JP. Three-dimensional imaging in orthognathic surgery: The clinical application of a new method. *Int J Adult Orthodon Orthognath Surg.* 2002;17:318–330.
13. O'Grady KF, Antonyshyn OM. Facial asymmetry: Three-dimensional analysis using laser surface scanning. *Plast Reconstr Surg.* 1999;104:928–937.
14. Guyuron B. Precision rhinoplasty: Part I. The role of life-size photographs and soft-tissue cephalometric analysis. *Plast Reconstr Surg.* 1988;81:489–499.
15. Penn J. Breast reduction. *Br J Plast Surg.* 1955;7:357–371.
16. Westreich M. Anthropomorphic breast measurement: Protocol and results in 50 women with aesthetically perfect breasts and clinical application. *Plast Reconstr Surg.* 1997; 100:468–479.
17. Grossman AJ, Roudner LA. A simple means for accurate breast volume determination. *Plast Reconstr Surg.* 1980;66:851–852.
18. Schultz RC, Dolezal RF, Nolan J. Further applications of Archimedes' principle in the correction of asymmetrical breasts. *Ann Plast Surg.* 1986;16:98–101.
19. Tezel E, Numanoglu A. Practical do-it-yourself device for accurate volume measurement of breast. *Plast Reconstr Surg.* 2000;105:1019–1023.
20. Edsander-Nord A, Wickman M, Jurell G. Measurement of breast volume with thermoplastic casts. *Scand J Plast Reconstr Surg Hand Surg.* 1996;30:129–132.
21. Bulstrode N, Bellamy E, Shrotria S. Breast volume assessment: Comparing five different techniques. *Breast* 2001;10:117–123.
22. Kovacs L, Eder M, Hollweck R, et al. Comparison between breast volume measurement using 3D surface imaging and classical techniques. *Breast* 2007;16:137–145.
23. Nahabedian MY, Galdino G. Symmetrical breast reconstruction: Is there a role for three-dimensional digital photography? *Plast Reconstr Surg.* 2003;112:1582–1590.
24. Kovacs L, Eder M, Hollweck R, et al. New aspects of breast volume measurement using 3-dimensional surface imaging. *Ann Plast Surg.* 2006;57:602–610.
25. Galdino GM, Nahabedian M, Chiamonte M, Geng JZ, Klatsky S, Manson P. Clinical applications of three-dimensional photography in breast surgery. *Plast Reconstr Surg.* 2002;110:58–70.