

Special Topic

Labioplasty: Anatomy, Etiology, and a New Surgical Approach

Aesthetic Surgery Journal
31(5) 511–518
© 2011 The American Society for
Aesthetic Plastic Surgery, Inc.
Reprints and permission:
[http://www.sagepub.com/
journalsPermissions.nav](http://www.sagepub.com/journalsPermissions.nav)
DOI: 10.1177/1090820X11411578
www.aestheticsurgeryjournal.com


Oren M. Tepper, MD; Marcelo Wulkan, MD; and Alan Matarasso, MD

Abstract

Increasing numbers of women are seeking correction of labial hypertrophy for aesthetic and/or functional reasons. It is therefore important for plastic surgeons to become familiar with labioplasty surgical techniques. The authors review the history and current status of labioplasty surgery for practicing plastic surgeons, with particular emphasis on anatomy, diagnosis, indications, and various techniques.

Keywords

labioplasty, body contouring, labia minora, hypertrophy

Accepted for publication February 9, 2011.

The history of labioplasty dates back to ancient Egypt and was based on the Pharaonic belief in the bisexuality of gods.¹ Traditionally called *khafd* (reduction) or *tahara* (purification), the practice of labioplasty on school-aged girls still exists in some countries. Labioplasty procedures may vary from simple labia minora removal (first degree) to complete resection of the external genitalia, including labia majora and minora together with the clitoris (which is referred to as “Sudanese circumcision,” or fourth-degree labioplasty).¹ Of note, the term *labioplasty* is sometimes incorrectly interchanged with *female circumcision*, which should primarily be reserved for describing removal of the prepuce of the clitoral hood.

In contrast to the controversial labioplasty procedures being performed for religious reasons, many Westernized women seek labioplasty surgery for functional or aesthetic concerns. The National Health Service of England reported a near-doubling in the number of labial reductions from 1999 to 2005, and similar trends have been noted in the United States and worldwide.² A recent study from the Netherlands sampled 482 women, who had an average age of 25; 95% were familiar with reduction labioplasty, and 14% considered their labia minora to be abnormal in size.³ Although labioplasty procedures have traditionally been performed by gynecologists or urologists, this procedure is becoming more common in plastic surgery practices. Therefore, in this article, we provide a review of the procedure that will familiarize plastic surgeons with aesthetic

labioplasty, with particular emphasis on relevant anatomy, diagnosis, operative indications, and surgical approaches.

ANATOMY

Labioplasty refers to a surgical procedure to reduce the size of the labia minora. The labia minora (alternatively termed *nymphae* or *labium minus pudendi*) are two longitudinal, cutaneous folds that typically vary in size. They are situated internally between the labia majora, and they extend from the clitoris laterally and posteriorly on either side of the vulval vestibule. In a subset of women, the posterior ends of the labia minora may be joined across the midline by a fold of skin, named the frenulum labiorum pudendi (ie, fourchette or posterior commissure of the labia minora). Anteriorly, each labium minora divides into an upper and lower portion. The upper division

Dr. Tepper is Assistant Professor of Surgery, Albert Einstein College of Medicine, Bronx, New York. Dr. Wulkan is a plastic surgeon in private practice in São Paulo, Brazil. Dr. Matarasso is Clinical Professor of Surgery, Division of Plastic Surgery, Albert Einstein College of Medicine, Yeshiva University, New York, New York.

Corresponding Author:

Dr. Alan Matarasso, 1009 Park Ave, New York, NY 10028.
E-mail: matarasso@aol.com

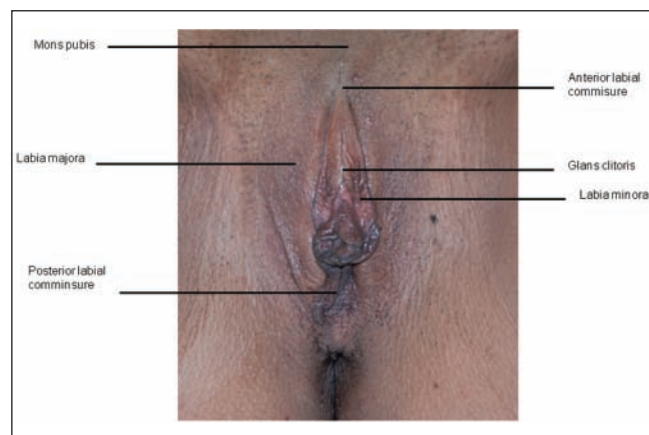


Figure 1. Labial anatomy. Anteriorly, each labium minora divides into an upper and lower portion. The upper division passes above the clitoris, to meet the contralateral side. In the superior portion, the labia minora are often asymmetric and form a fold, the preputium clitoridis, which overhangs the glans clitoridis. Along the opposing surfaces of the labia minora are numerous sebaceous follicles.

passes above the clitoris, to meet the contralateral side. In this superior portion, the labia minora are often asymmetric and form a fold, the preputium clitoridis, which overhangs the glans clitoridis. Along the opposing surfaces of the labia minora are numerous sebaceous follicles (Figure 1).

Sensory innervation to the labia minora is predominately provided by perineal branches and the posterior labial branches of the pudendal nerve. The clitoris is unique in that it consists of many nerve endings, receiving additional autonomic innervation from the pelvic and hypogastric plexus. The vascular supply to this region consists of branches from the internal pudendal artery (peroneal, posterior labial, and dorsal clitoral artery).

Labial Hypertrophy

Labial hypertrophy may simply be a normal variant. Additionally, asymmetry of the female genitalia is a natural occurrence, thus making a clear distinction between normal and abnormal anatomy challenging. Felicio⁴ has proposed a classification system for hypertrophy of the labia minora based on length: less than 2 cm (Type I), 2 to 4 cm (Type II), 4 to 6 cm (Type III), and more than 6 cm (Type IV) (Table 1).⁴ Some physicians believe that 5 cm is the upper limit of normal labial size.

Labial hypertrophy is most commonly congenital in origin.^{5,6} Acquired causes, however, must be considered. These include a number of potential etiologies, such as exogenous androgenic hormones in infancy,⁷ sensitivity to topical estrogen,⁸ stretching or weight attachment of the labia (ie, in the Hottentot tribe),⁹ dermatitis secondary to urinary incontinence, vulvar lymphedema (ie, infection by *Filaria sanguinis hominis*, which invades lymph channels),¹⁰ and myelodysplastic diseases.¹¹ Some also believe that repetitive stretching, which can occur with multiple pregnancies, might also contribute to labial hypertrophy (Table 2).

Table 1. Felicio Classification of Labial Hypertrophy⁴

Type I	Less than 2 cm
Type II	2-4 cm
Type III	4-6 cm
Type IV	More than 6 cm

Table 2. Common Etiologies of Labial Hypertrophy

Idiopathic
Medication related
<ul style="list-style-type: none"> • Exogenous androgenic hormones in infancy • Sensitivity to topical estrogen
Inflammation related
<ul style="list-style-type: none"> • Local dermatitis (urinary incontinence) • Vulvar lymphedema (ie, infection by <i>Filaria sanguinis hominis</i>) • Myelodysplastic disease
Chronic/repetitive stretching or overexpansion
<ul style="list-style-type: none"> • Multiple pregnancies

A protruding labia minora that extends beyond the labia majora may lead to psychological, cosmetic, or functional problems. Labial hypertrophy causes loss of self-esteem and embarrassment for some women.⁵ Even in the absence of psychosocial factors, enlarged labia minora can lead to functional difficulties. Issues that may arise secondary to labial hypertrophy include interference with sexual intercourse, chronic local irritation, problems with personal hygiene during menses or after bowel movements, and discomfort during walking, cycling, or sitting.^{4,6-10,12,13} Moreover, with current fashion trends being more revealing and form-fitting, the abnormal appearance of the enlarged labia minora can be magnified. During consultation, it is worthwhile for physicians to ask about these various symptoms and concerns to determine whether the condition warrants surgical correction.

SURGICAL TECHNIQUES

Despite the increasing prevalence of labioplasty procedures, published reports describing labioplasty techniques remain sparse.⁸ No single ideal approach exists for labioplasty, and each has unique advantages and disadvantages. Overall goals of labioplasty include (1) reduction of the hypertrophic labia minora, (2) maintenance of neurovascular supply, (3) preservation of introitus, (4) optimal color/texture match of labial edge, and (5) minimal invasiveness (Table 3).¹⁴ Because of frequent variations in size, shape, and symmetry between the two labial sides, familiarity with different techniques (which

Table 3. Goals of Labioplasty

• Reduction of hypertrophic labia minora
• Maintenance of neurovascular supply
• Preservation of introitus
• Optimal color/texture match of labial edge
• Minimal invasiveness

are sometimes combined in the same patient) is necessary and desirable. The following discussion offers a brief summary of the labioplasty techniques that have been reported in the literature (Table 4).

Elliptical and Wedge Excision

In 1984, Hodgkinson and Hait⁸ described the first technique for labioplasty through an elliptical excision. Their report

included three cases of labial reduction surgery performed for social embarrassment and diminished sexual sensitivity. All operations were performed under either local or general anesthesia. Key surgical principles highlighted in the article included (1) limiting the resection to areas outside the fourchette in order to avoid distortion of the urethral orifice and (2) leaving a minimum labial length of 1 cm, maintaining protrusion past the introitus. The authors reported successful outcomes and patient satisfaction in all three cases.

Alter⁵ subsequently described a “V-shaped” wedge resection centered over the most protuberant part of the hypertrophied labia (Figure 2A).^{10,15} The author treated four patients with this technique, in which the direction and angle of the wedge can be adjusted according to the need for excision, predominantly anteriorly or posteriorly. Key aspects noted by Alter included (1) avoiding overresection of the labia in order to prevent an overly tight introitus and pulling during sexual intercourse and (2) similarly limiting the excision to outside of the fourchette. Of note, one disadvantage of this technique is that in order to incorporate enough excess labia in the resection, the excision approaches the labia majora. Consequently, variations

Table 4. Labioplasty Techniques in the Literature

Technique	Reference	n	Indications	Anesthesia	Advantages/Disadvantages	Sutures	Postoperative Foley Catheter	Postoperative Packing
Elliptical excision	Hodgkinson et al (1983) ⁸	3	Interference with sexual intercourse Social embarrassment	General or local	Technical ease	Prolene or chromic		
Wedge excision	Alter (1998) ⁵	4	Social embarrassment		Technical ease Flexibility in design (ie, preferential anterior vs posterior excision)	Vicryl	No	No
	Alter (2008) ¹⁶	407	Social embarrassment Interference with sexual intercourse Lesion (ie, hemangioma)		Technical ease Flexibility in design (ie, preferential anterior vs posterior excision)	Monocryl		
	Rouzier et al (2000) ¹⁰	163	Aesthetic Discomfort with exercise Discomfort with clothing Discomfort with sex		Posteriorly-designed wedge excision Preservation of free edge of labial minora Can easily adjust size of excision	Vicryl		
	Munhoz et al (2006) ¹⁵	21	Social embarrassment Poor hygiene Interference with sexual intercourse	Local		(Resorbable)	No	No
Zig-zag technique	Maas and Hage (2000) ¹²	13		General or local	Loss of pigmentation	(Resorbable)	No	No
Deepithelialization	Choi and Kim (2000) ¹⁷	6	Interference with sexual intercourse Social embarrassment Poor hygiene	General or local	Preservation of natural color and texture of labial edge	Catgut		
Double-wedge technique (“star” labioplasty)	Current report (Matarasso technique)	8	Social embarrassment	General	Flexibility in design (preferential excision)	Chromic or Vicryl ± Dermabond	No	No

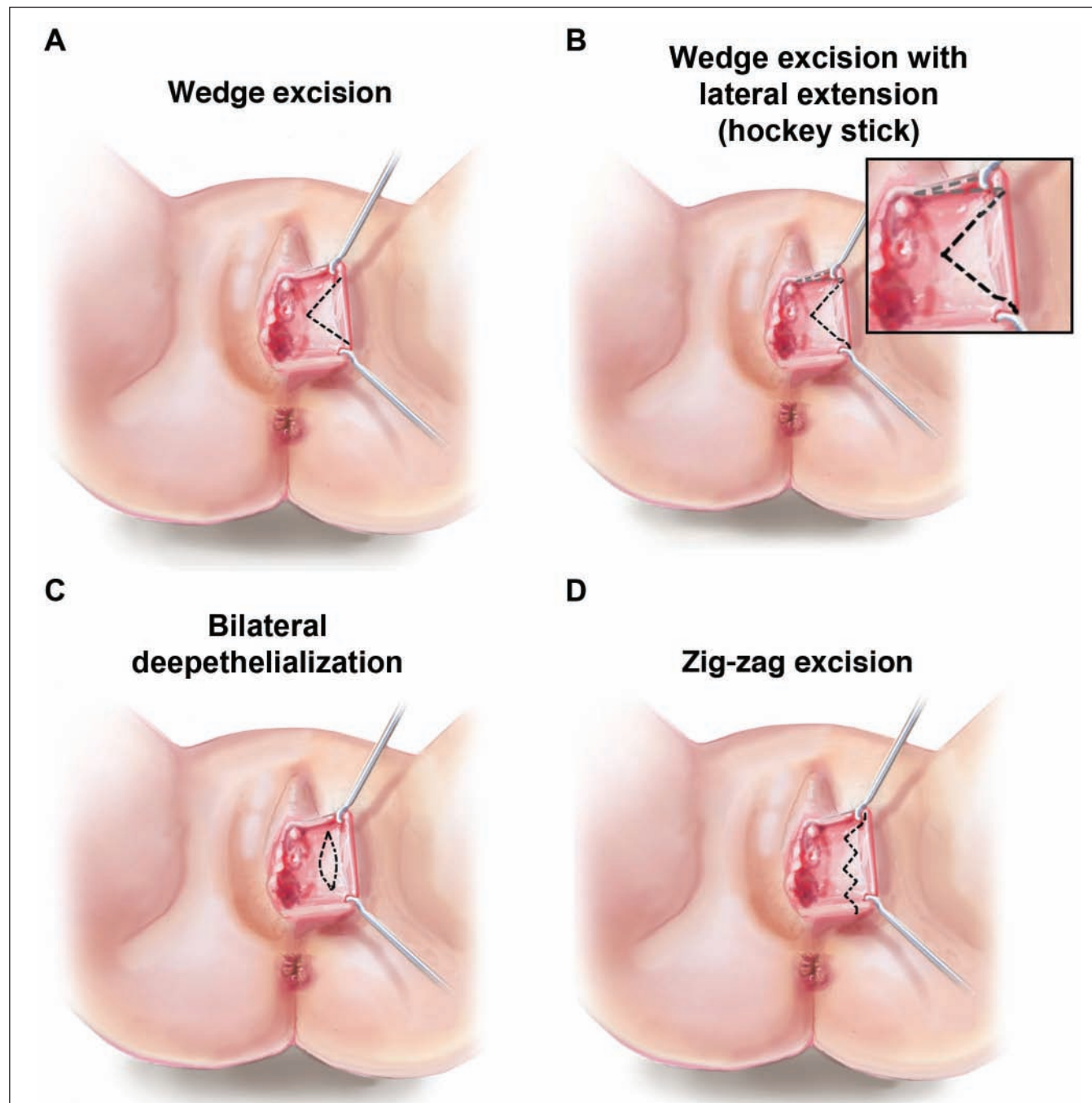


Figure 2. Schematic drawings of surgical approaches for labial minora reduction. (A) Wedge excision; (B) Wedge excision with lateral extension (“hockey stick V”); (C) Bilateral deepithelialization; (D) Zig-zag excision.

or combinations may be necessary in order to achieve an adequate reduction.

Extended Central-Wedge Excision

Recently, Alter¹⁶ reported a follow-up study of central wedge excision in 407 patients. This series is the largest to

date and provides data on a wide range of patients undergoing labioplasty for primarily aesthetic concerns or discomfort (98.8%). Alter utilized his original wedge technique, which was designed as an internal wedge and oriented along the most protuberant portion of the labia minora, but he also described the potential addition of an external wedge (“hockey stick V”) that is curved laterally and anteriorly to remove excess lateral clitoral hooding or

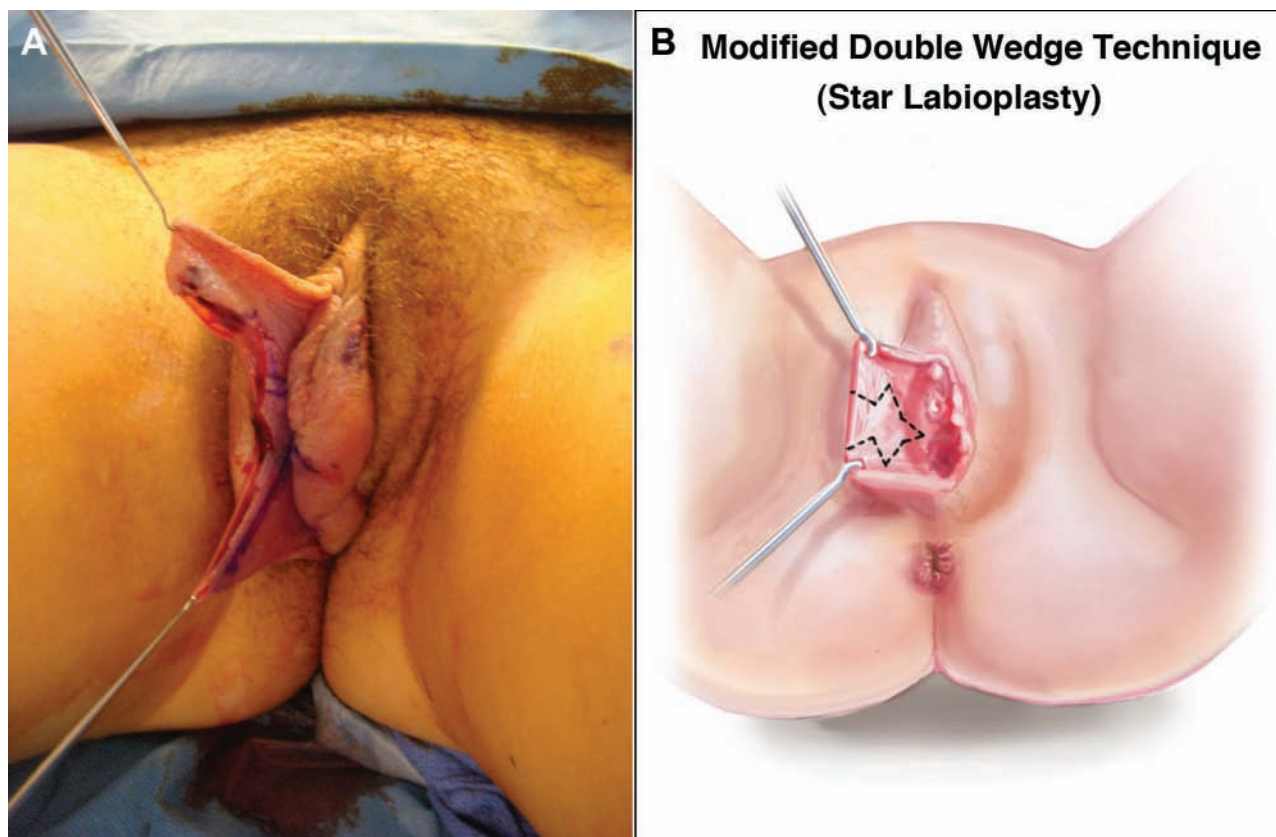


Figure 3. (A) This intraoperative photograph depicts the senior author's (AM) modification of a wedge excision utilizing four limbs, also referred to as the "star" technique. This approach enables greater flexibility to preferentially excise the labia minora by altering the size or angle of the "V" and adding one or two horizontal wedge resections. (B) The illustration clearly depicts the incision pattern for the authors' "star" labioplasty.

dog-ear (Figure 2B). Alter also purported that his internal wedge technique decreased the likelihood of wound edge separation, sinus/fistula formation, clitoral hood excess, and postoperative pain.

Munhoz et al¹⁵ reported on a modified-wedge approach to labioplasty in a series of 21 patients. Their description included a superior pedicle flap. This approach utilized an inferiorly based "wedge" while maintaining a pennant of tissue that could be rotated to reconstruct the inferior defect. The authors stated that the advantage to their approach was the superior flap with a free margin of labial tissue with natural color and texture.

Bilateral Deepithelialization

A novel approach to labioplasty was described by Choi and Kim¹⁷ in 2000; the authors reported their experience with central excision and bilateral deepithelialization in six patients (Figure 2C). With this technique, the central area of hypertrophy is marked on both the medial and lateral sides, and both sides are deepithelialized. Unlike other techniques for labial minora reduction, this approach is unique in that it preserves the entire edge of the labia.

By limiting the incision to the central portion of the labia minora, this technique offers the potential for improved neurovascular supply, preservation of sensation, and optimal maintenance of the natural color and texture of the labial edge. Moreover, this technique may be less susceptible to postoperative tightness or pulling at the introitus. Of note, Choi and Kim highlighted the importance of leaving a minimum of 1 cm of labial length, similar to what was described previously.

Zig-Zag Technique

Maas and Hage¹² reported their experience with labioplasty through a zig-zag technique in 13 patients. Their approach resembled traditional approaches (ie, elliptical excision, wedge excision) by directly addressing the protuberant edge of the labia minora but was unique in that the authors performed a running W-shaped resection with interdigitated suturing of the protuberant labium (Figure 2D). Some believe the rounded contour of the labia minora's edge may be re-created more successfully with this technique, but potential loss of the dark pigmentation along the labial edge is a concern. Maas and Hage also

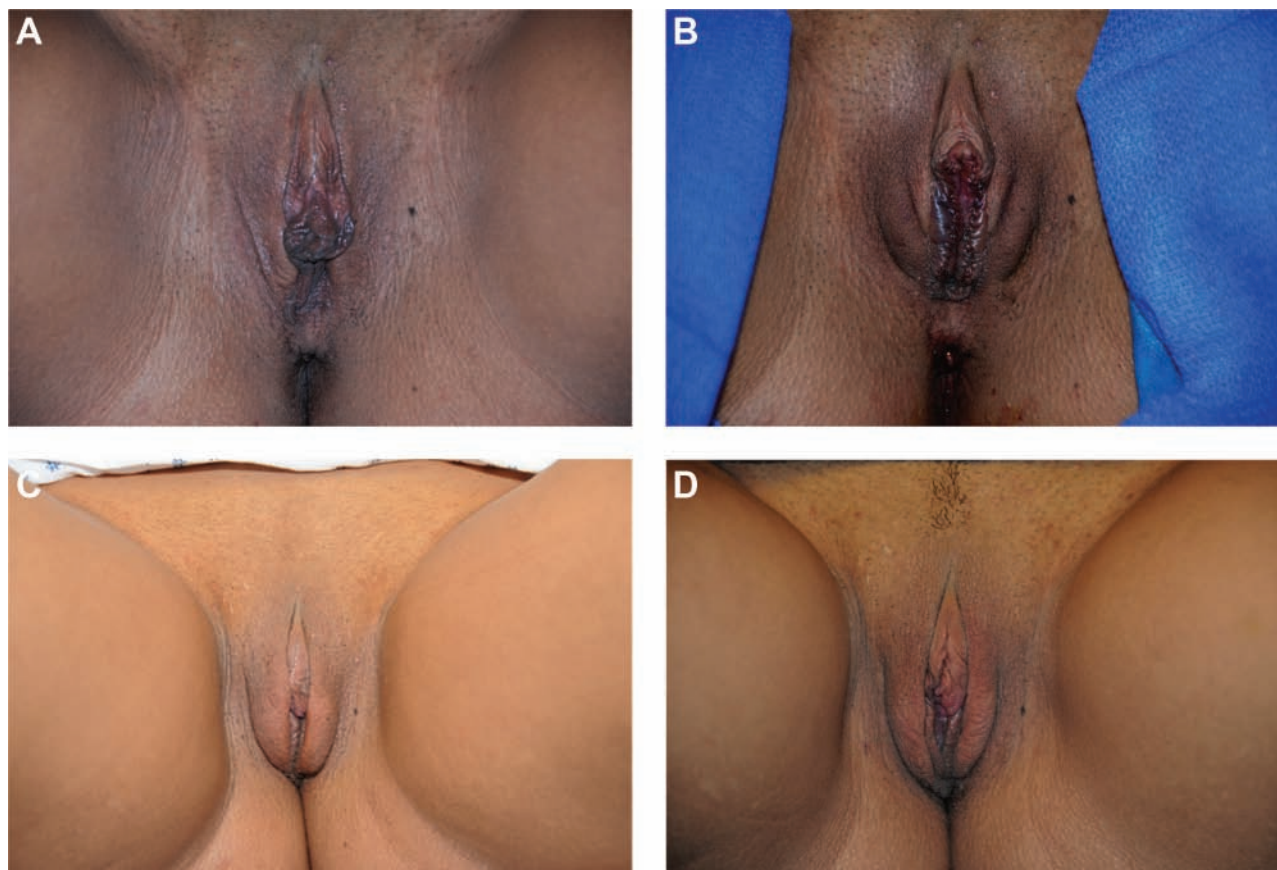


Figure 4. (A) This 22-year-old woman who presented for treatment of labial hypertrophy is shown immediately preoperatively. (B) Immediately after labioplasty with the authors' new double-wedge "star" labioplasty technique. (C) One month postoperatively. (D) Two months postoperatively. (Photos courtesy of Dr. David Shafer)

stressed avoiding extension into the dorsal hood or posterior fouchette and leaving a minimal cuff of 1 cm on the labia minora to allow for slight protrusion.

Modified Double Wedge Resection ("Star" Labioplasty)

On the basis of previous reports from Alter and Munhoz, the senior author (AM) has devised a modified wedge approach to labioplasty, termed the "star" labioplasty. Early descriptions of the wedge excision highlighted the surgeon's ability to tailor the size, angle, and orientation of the "V" in order to best excise the area of protuberance. In an effort to gain further flexibility, the senior author designed this star labioplasty, which can be individualized to each patient. This approach has proven advantageous when sufficient tissue cannot be removed with simple vertical wedge excision. With this technique, increased tissue removal is achieved by adding a horizontal wedge to the central "V," which can be oriented horizontally or angled according to the location of the excess tissue.

In this procedure, the labia is stretched and a vertical wedge is drawn. Any excess labia is then removed by

adding an additional wedge midway down the V-limb unilaterally or bilaterally (Figure 3). Again, the dissection of an additional "V" wedge enables greater flexibility with the excision. For example, if preferential excision of the labia is desired posteriorly, one can design a larger posterior "V" at a greater angle, thus allowing the anterior labial edge to be moved posteriorly. This technique provides additional reduction in the horizontal dimension of the labia, without the risk of widening the central "V" to an inappropriately large degree, which would encroach upon the labia majora. Similar to the advantages described by Munhoz, the authors believe this "star" approach provides an abundant amount of a natural, nonviolated, labial edge. Clinical results from this technique can be seen in Figure 4.

DISCUSSION

To date, few techniques for aesthetic labioplasty have been described in the literature. Recent changes in fashion trends, including more revealing attire, have contributed to an increased demand for contouring of the labia minora. Functional considerations also remain an important

LABIOPLASTY DATA SHEET

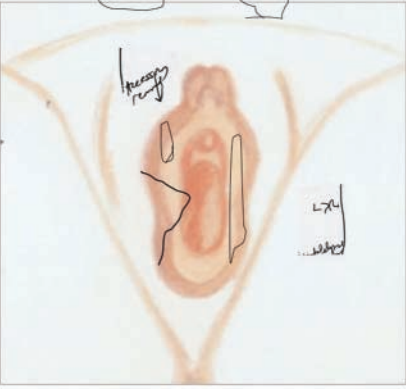
Patient Name: [REDACTED] MR#: [REDACTED]

Surgery Date: [REDACTED]

Anesthesia: General

Operative Technique:

Right Left



Operative Notes: Right sided wedge - angled posteriorly.
 Accessory portion removed anteriorly. Left de-epithelialization
 Postoperative Course:

Figure 5. The authors' clinical data sheet for labioplasty. Note that this patient required different approaches on each side, tailored to her specific anatomy.

motivation for surgical treatment, with recent reports suggesting that the majority of patients are undergoing reduction of the labia minora today for functional reasons, with minimal outside influences affecting their decision for treatment.^{16,18} Consequently, the role of insurance coverage for "functional labioplasty" may be an important issue for surgeons in the future. Regardless, plastic surgeons should consider both the aesthetic and functional issues associated with labial hypertrophy.

Although some surgeons may have a preferred technique, it behooves all of us to familiarize ourselves with all of the various labioplasty approaches. It is not uncommon to encounter significant asymmetry between the two labia, and thus different approaches may be required for each side. The authors have often found this to be the case with their patients. Figure 5 represents an example of an operative data sheet from the authors' private clinic, which shows how two different approaches were used. The resection was greater on the right labia; a caudally oriented "V" wedge was excised and an accessory portion was directly excised superiorly for further reduction. On the left side, a wedge was deepithelialized. In retrospect, we would have preferred the newer "star" technique—the modified wedge, with a vertical wedge and one or two horizontal wedges—as described above and shown in Figure 3.

Most studies on aesthetic labioplasty suggest that the procedure is associated with a high level of patient satisfaction. In a study of 163 patients, Rouzier et al¹⁰ reported satisfaction rates of 89% and 93% in terms of aesthetic and functional outcomes, respectively. Similar levels of patient satisfaction have been reported by Munhoz et al,¹⁵ with over 95% of patients being satisfied with aesthetic results and no instances of disappointment or regret with the procedure. Alter¹⁶ reported that of 163 patients who responded to his questionnaire, 98% would elect to undergo the surgery again and 95% rated their "happiness" with the surgery as an eight or higher (out of 10). Goodman et al¹⁹ recently reviewed a group of 177 patients who had undergone labioplasty and/or clitoral hood reduction by either a gynecologist (82%) or plastic surgeon (28%). The most common indications for surgery included a desire to look better (94%), enhance self-esteem (33%), feel more normal (31%), and avoid discomfort (76%). The overall patient satisfaction rate was 97.2%.

Postoperative care is an essential component in the overall management of patients undergoing labioplasty procedures. Unfortunately, existing literature on labioplasty surgery provides little detail on the postoperative course. In our experience, patients experience moderate postoperative discomfort for up to two weeks, which can be partially alleviated with anti-inflammatory drugs and ice packs. We stress the need for good hygiene in order to prevent infection. Furthermore, we recommend that patients avoid sexual relations for four weeks, but this recommendation is largely subjective.

Labioplasty surgery is associated with a number of potential complications. Well-known complications include distal flap necrosis, hematoma, superficial infection, skin retraction, late local pain, and transient dyspareunia.^{10,15} Munhoz et al¹⁵ reported in their cohort of 21 patients occurrences of localized hematoma (n = one), infection (n = one), and wound dehiscence (n = two). Mass and Hage¹² reported similar outcomes, with one patient in their study suffering from a localized hematoma and one from wound dehiscence.

In our experience, postoperative wound dehiscence is the most common adverse event and is particularly difficult to manage given the unique physiology of the labia, including possible increased tenderness and difficulty maintaining dampness. Whether the suture material (permanent vs resorbable) or technique (running vs interrupted, or one or two layers) affects the rate of dehiscence remains unknown, with no apparent consensus within the literature. Alter⁵ described the use of Vicryl sutures (Ethicon, Inc., Somerville, New Jersey) in his initial description of the wedge resection, whereas Hodgkinson and Hait⁸ reported on chromic gut (overwhelmingly the most commonly used suture) and permanent sutures (4-0 Prolene; Ethicon, Inc.) removed at seven days. In Alter's recent report of his modified technique,¹⁶ he utilized 5-0 Monocryl (Ethicon, Inc.) sutures placed in *at least* three layers; vertical mattress sutures were used for the leading labial edge, a running Monocryl was placed for the remainder of the medial edge, and interrupted sutures were inserted for the lateral edge. (Nonabsorbable sutures may help prevent dehiscence.) Labial separation occurred in 12 of 407 patients, but all instances were reported as minor.

Regardless of suture type, one should aim for a tension-free closure to minimize the risk of dehiscence and recognize that postoperative edema in this friable tissue can confound even the most exacting closure. In our small patient cohort, we have had issues with wound dehiscence in two of eight patients. Anecdotally, we found that Dermabond (Ethicon, Inc.) served as a useful adjunct in maintaining wound edge adherence when issues of wound separation arose.

CONCLUSIONS

Labia minora reduction is an increasingly common, straightforward procedure that can yield a high degree of patient satisfaction. Here, we reviewed the history, anatomy, etiology, and literature on labioplasty. We also provided a description of our modified “star” technique, with which we have had no cases of revision or reoperation for insufficient reduction in a small series of patients.

Disclosures

The authors declared no potential conflicts of interest with respect to the authorship and publication of this article.

Funding

The authors received no financial support for the research and authorship of this article.

REFERENCES

- Hosken FP. The epidemiology of female genital mutilations. *Trop Doct* 1978;8:150-156.
- Liao LM, Creighton SM. Requests for cosmetic genitoplasty: how should healthcare providers respond? *BMJ* 2007;334:1090-1092.
- Koning M, Zeijlmans IA, Bouman TK, van der Lei B. Female attitudes regarding labia minora appearance and reduction with consideration of media influence. *Aesthetic Surg J* 2009;29:65-71.
- Felicio Y. Chirurgie Intime. *La Ver Chir Esth Lang Franc* 1992;67.
- Alter GJ. A new technique for aesthetic labia minora reduction. *Ann Plast Surg* 1998;40:287-290.
- Radman HM. Hypertrophy of the labia minora. *Obstet Gynecol* 1976;48:78S-79S.
- Chavis WM, LaFerla JJ, Niccolini R. Plastic repair of elongated, hypertrophic labia minora: a case report. *J Reprod Med* 1989;34:373-375.
- Hodgkinson DJ, Hait G. Aesthetic vaginal labioplasty. *Plast Reconstr Surg* 1984;74:414-416.
- Capraro VJ. Congenital anomalies. *Clin Obstet Gynecol* 1971;14:988-1012.
- Rouzier R, Louis-Sylvestre C, Paniel BJ, Haddad B. Hypertrophy of labia minora: experience with 163 reductions. *Am J Obstet Gynecol* 2000;182:35-40.
- Kato K, Kondo A, Gotoh M, Tanaka J, Saitoh M, Namiki Y. Hypertrophy of labia minora in myelodysplastic women: labioplasty to ease clean intermittent catheterization. *Urology* 1988;31:294-299.
- Maas SM, Hage JJ. Functional and aesthetic labia minora reduction. *Plast Reconstr Surg* 2000;105:1453-1456.
- Gowen RM, Martin VL. Labia minora reduction in an iron-lung disabled woman. *Obstet Gynecol* 1988;71:488-489.
- Assaad MB. Female circumcision in Egypt: social implications, current research, and prospects for change. *Stud Fam Plann* 1980;11:3-16.
- Munhoz AM, Filassi JR, Ricci MD, et al. Aesthetic labia minora reduction with inferior wedge resection and superior pedicle flap reconstruction. *Plast Reconstr Surg* 2006;118:1237-1247; discussion 1248-1250.
- Alter GJ. Aesthetic labia minora and clitoral hood reduction using extended central wedge resection. *Plast Reconstr Surg* 2008;122:1780-1789.
- Choi HY, Kim KT. A new method for aesthetic reduction of labia minora (the deepithelialized reduction of labioplasty). *Plast Reconstr Surg* 2000;105:419-422; discussion 423-424.
- Miklos JR, Moore RD. Labioplasty of the labia minora: patients' indications for pursuing surgery. *J Sex Med* 2008;5:1492-1495.
- Goodman MP, Placik OJ, Benson RH III, et al. A large multicenter outcome study of female genital plastic surgery. *J Sex Med* 2010;7(pt 1):1565-1577.